

Chapter 4

To Transplant or Not to Transplant – That Is the Question

Sherman J. Silber, Teresa K. Woodruff, and Lonnie D. Shea

Introduction

Successful fresh human ovary transplantation was first reported between monozygotic twins discordant for premature ovarian failure (POF) using a cortical grafting technique [1, 2]. Normal menstrual cycles resumed after 4 months, and spontaneous pregnancy leading to a healthy child occurred 1 month later. Subsequently, a series of seven more consecutive successful cases was reported, for a total of eight, all demonstrating normal ovulatory menstruation [3, 4]. A ninth successful case using a different technique, microvascular intact whole ovary transplantation, was reported recently, again with return of normal ovulatory cycles, spontaneous pregnancy, and delivery of a healthy child [5]. This unusual series of ovary transplants between monozygotic twin sisters afforded a remarkable opportunity to study the effect of transplant ischemia and cryopreservation on the success of fresh and frozen ovarian grafts without the concern of immunosuppression. We can apply the techniques of cryopreservation and transplantation gleaned from these transplants to preserve fertility in patients who are about to undergo otherwise sterilizing cancer treatment.

The indication in all of these cases was complete ovarian failure (POF) in one sister who wished to have children, whereas the other sister was fertile and already had her family complete. In each case, careful consideration was given to other treatment options such as donor egg IVF and adoption. Thus far, 12 pregnancies and 8 healthy babies have resulted from these nine homozygotic transplants. In seven of these nine fresh ovary transplants between monozygotic non-rejecting sisters, some ovarian cortical tissue was frozen for a future grafting, in case the transplanted ovary would run out of eggs and cease to function [6]. Our results in these monozygotic twins with discordant ovarian failure, using both fresh and frozen ovarian grafts, form the basis of our technical improvements in ovary freezing and transplants for young cancer patients. “These strategies are reviewed with their technical and utilization limitations; and a discussion will be provided of the next steps that will

S.J. Silber (✉)
Infertility Center of St. Louis, St. Louis, MO, USA
e-mail: sharon@infertile.com

proceed eventually to the first attempt at fertilization of an oocyte from an in vitro matured human follicle with embryo transfer, which can be applied in cases where ovarian tissue transplantation is not recommended.”

Transplant Technologies and Their Success

First we needed to distinguish between the effect of ischemia time versus that of cryopreservation, and how to reduce oocyte loss from both. We have eliminated ischemic damage with intact whole ovary microsurgical transplantation, but this technique is much more difficult than cortical grafting and is complex and risky [5]. So cortical grafting is best for popular acceptance. However, the simpler cortical graft technique in the past had been problematic, with only sporadic reported success. For example, a dramatic loss of oocytes had been noted in some studies of ovarian cortical grafting in animals [7]. But in other animal studies apparently normal lifetime graft survival has been observed [8]. In one human study, there was a maximum graft survival lifetime of only 2 years, but the clinical situation was very convoluted, i.e., older women undergoing hysterectomy and oophorectomy [9]. In the cases of autotransplantation of thawed ovarian tissue in cancer patients, successful results have been few and very sporadic at best [6, 10–12]. It has not been clear whether these problematic outcomes are due to cryopreservation damage, or to the ischemia time after cortical grafting until revascularization occurs, or in some cases simply to prior damage from chemotherapy [13].

We have eliminated these concerns in our series of monozygotic sisters and also in frozen autografts. In 12 of these procedures, 9 fresh and 3 frozen, we have demonstrated the surgical robustness of the procedure when there are no immunological concerns, and with improved methods of cryopreservation [14]. In this study, we have observed in humans that fresh cortical ovarian grafts result in very little oocyte loss and yield normal duration of function (when using microsurgical techniques). Furthermore, we have found that although slow-freezing results in over a 60% loss of oocyte viability, vitrification may mitigate this cryo-induced oocyte loss, and there should therefore be no obvious difference in results between fresh or frozen cortical grafts (Fig. 4.1). Finally, only one out of the nine cases failed to conceive spontaneously (a 40-year-old woman), and all patients but one have one or more live babies resulting from this procedure.

It is estimated that two normal ovaries in a 25-year-old with normal ovarian reserve should yield approximately 26 years of function [15]. Therefore, one-fourth of one ovary might be expected to represent one-eighth of normal ovarian reserve in a typical 25-year-old. Thus, 3–4 years of graft function would be compatible with minimal loss of oocytes. We used the duration of fresh graft function as a baseline, and then compared oocyte viability in a strip of fresh graft to frozen thawed grafts cryopreserved by slow freeze versus vitrification. Thus, we estimated the overall duration of function of cortical grafts and evaluated the oocyte loss to be minimal.

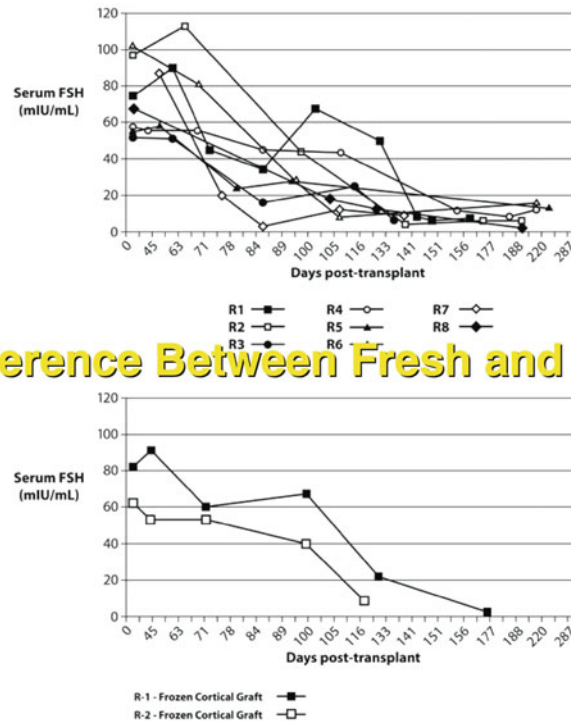


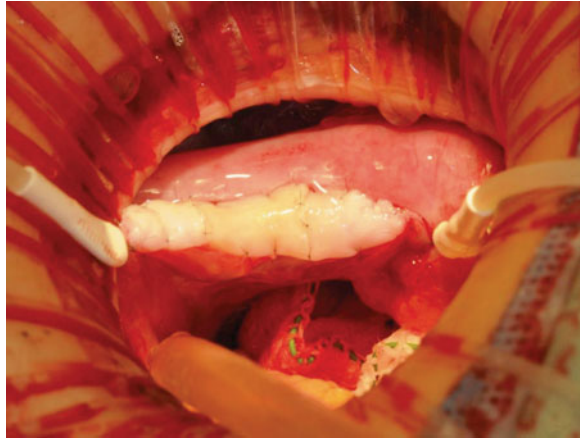Fig. 4.1 There is no difference in the rate of return of serum FSH to normal between fresh and frozen ovarian grafts

Surgical Technique

Under general anesthesia, one ovary was removed intact by laparoscopy or by mini-laparotomy and the cortex was transplanted onto the decorticated medulla of the recipient (Fig. 4.2). The donor ovary is transferred to a Petri dish with Leibowitz (L-15) medium that is placed upon cold saline ice slush. It is then dissected ex-vivo into thin strips of cortex. The following surgical principles were applied in all cases: (a) thin the cortical tissue down to a bare 0.75–1.0 mm to promote more rapid revascularization, (b) obtain perfect hemostasis of graft bed with micro-bipolar forceps, (c) suture securely with 9-0 nylon interrupted sutures to prevent micro-hematoma formation under the graft, (d) use the ovarian medulla to obtain the richest angiogenic factors and the most rapid graft revascularization, and (e) continual pulsatile irrigation with heparinized saline to prevent adhesion formation [2, 4, 5].

The normal predicted survival of ovarian grafts in our series of patients demonstrates that there is probably not a huge oocyte loss from the transplant itself, similar to our autotransplantation studies in cattle [14]. The reason for our high success with fresh cortical grafts could be related to a surgical technique that avoids micro-hematoma formation under the graft, and uses a very thin 0.75-mm slice of cortex.

Fig. 4.2 Completed ovarian cortical graft through minilap incision



Plastic surgeons use pressure dressings over skin grafts to avoid this most common cause of graft ischemia and delayed vascularization. Since we have no such option intra-abdominally, we use multiple minuscule stitches of 9-0 or 10-0 nylon sutures, and prepare the graft bed carefully with pinpoint microbipolar hemostasis while at the same time employing constant irrigation with heparinized saline to avoid adhesion formation. Finally, it is probable that an orthotopic location allows for better ovarian function than a heterotopic one, perhaps due to more normal tissue pressure during ovarian follicle maturation [16, 17–19].

The question comes up whether cortical tissue grafts are as favorable as a microvascular whole ovary transplant as suggested by Bedaiway and Falcone [20, 21]. Thinking that this might avoid the ischemia time associated with waiting several days for the medullary graft bed to revascularize the transplanted cortex, we performed a successful case of microvascular whole intact ovary transplant in a woman who was more interested in long-term function than pregnancy [5]. She began to spontaneously cycle and ovulate, and conceived a healthy baby girl. Unfortunately, this is a difficult and major operation that requires very extensive micro-vascular surgical expertise, and cryopreservation of an intact whole ovary is more problematic than vitrification of a cortical tissue slice.

Ovarian Tissue Vitrification

For vitrification, the ovary cortex was cut into pieces $1 \times 10 \times 10$ mm. The precise 1-mm tissue thickness was guaranteed with a tissue slicer designed explicitly for this purpose. The tissue slicer plate has a $1 \times 10 \times 10$ mm cubic space. The ovary is cut between the slicer and the surface of ovary using a sharp edge. The ultra-thinness of the tissue is thought to be crucial, not only for the cryopreservation but also for the rapidity of revascularization after grafting. Ovarian tissues are initially equilibrated in 7.5% ethylene glycol (EG) and 7.5% dimethyl sulfoxide (DMSO) in handling

medium [HM; HEPES-buffered TCM-199 solution supplemented with 20% (v/v) synthetic serum substitute (SSS; Irvine Scientific, Santa Ana, CA, USA)] for 25 min followed by a second equilibration in 20% EG and 20% DMSO with 0.5 mol/l sucrose for 15 min, or until the tissue sinks to the bottom of the test tube indicating complete absorption. Ovarian tissues are then placed in a minimum volume of solution onto a thin metal strip (Cryotissue; Kitazato BioPharma, Fujinomiya, Japan), and submerged directly into sterile liquid nitrogen, following which the strip was inserted into a protective container and placed into a liquid nitrogen storage tank. For warming, the Cryotissue metal strip is immersed directly into 40 ml of 37°C HM solution supplemented with 1.0 mol/l sucrose for 1 min. Then, ovary tissues are transferred into 15 ml of 0.5 mol/l sucrose HM solution for 5 min at room temperature and washed twice in HM solution for 10 min before either viability analysis or transplantation.

Fresh ovarian tissues (examining 358 oocytes) were not significantly different in oocyte viability from vitrified tissues (examining 1,122 oocytes) for a 91.9% and an 89.1% viability rate, respectively. Slow-freeze ovarian tissue by contrast (examining 821 oocytes) demonstrated an oocyte viability rate of only 41.7%. Vitrification resulted in minimal if any oocyte loss, similar to previous findings in cattle [14]. Thus, freezing by vitrification is not likely to seriously harm the results with ovarian cortical grafting.

Preserving Fertility in Cancer Patients

The major reason for the current intense interest in ovary freezing and transplantation is that at least one in 250 women of reproductive age [22] are cancer survivors. Today, 90% of these young women will be cured of their cancer [23, 24]. Yet the very treatment which will cure them usually compromises their fertility by destroying all or a large part of their ovarian follicle reserve [10, 25–27]. Most such young women with cancer are highly interested in trying to preserve their fertility so they might have children in the future [28, 29]. However, their treatment is likely to reduce their fertility or render them completely sterile. Also, for children, pediatric patients may not understand the full implications of cancer treatment for future parenthood, but fertility preservation is equally important for them, and they do not have the option of using IVF technology for oocyte or embryo banking.

A secondary reason for the current interest in fertility preservation is an increasing delay in age in developed countries for women to try to conceive [30–33]. Yet fertility naturally declines with age in all women, even those who have no other health problems. This reduced fertility in women from their teen years to their early 1940s is caused by a decreasing number and decreasing quality of their eggs [34–37]. Thus, we are experiencing a worldwide epidemic increase in infertility caused simply by ovarian aging.

The uterus does not seem to play a significant role in this age-related decline in fertility as evidenced by the high pregnancy rate in older women using eggs donated

from younger women [36]. Therefore, it has been widely hoped that ovarian cryopreservation and subsequent transplantation of thawed tissue years later, after the patient has been cured of cancer or wishes to have children, could be an effective resolution to this dilemma [1]. In fact, thus far in humans there have been 13 healthy babies born from fresh or frozen ovarian grafting (Table 4.1).

Table 4.1 Delivered pregnancies after transplanting fresh and cryopreserved ovarian tissue (13 babies). The worldwide experience with ovary transplantation, both frozen and fresh, is obviously quite robust

Patient type	Transplant	Country	References
Premature ovarian failure	Fresh MZ twin orthotopic cortical strip	USA	Silber et al. (2005) 7 babies
Hodgkin's lymphoma	Frozen autograft orthotopic cortical strip	Belgium	Donnez et al. [16]
Non-Hodgkin's lymphoma	Frozen autograft orthotopic cortical strip	Israel	Meirow et al. [34]
Ewing's sarcoma	Frozen autograft orthotopic cortical strip	Denmark	Andersen et al. (2008)
Hodgkin's lymphoma	Frozen autograft orthotopic cortical strip	Belgium	Demeestere et al. [13]
Premature ovarian failure	Frozen MZ twin orthotopic cortical strip	USA	Silber et al. [38] 1 baby

Although thousands of ovarian tissue samples have been banked in clinics worldwide, clinical success rates cannot be defined yet because very few women have had a transplant after cancer treatment, and none for ovarian ageing. While the MZ twin series involved histocompatible donor tissue instead of an autograft, and healthy individuals rather than cancer patients, this is the largest series of ovarian transplants to date and provides rare information for guiding fertility preservation practices and counseling patients about the likelihood of success.

As mentioned in the *Introduction* section, transplantation ischemia has sometimes been considered to be a more limiting factor for the functional lifespan of grafts than cryopreservation per se. This conclusion was however drawn from experiments in which bovine tissue was xenografted to SCID-mice, using the kidney capsule instead of the orthotopic site [7]. It would be unreasonable to expect such a transplant not to suffer severe oocyte loss irrespective of any additional cryoinjury. Since a balanced experimental design is not feasible in human patients for ethical reasons, it is difficult to draw inferences about the impact of ischemia except for radically different surgical strategies. Ischemia time is reduced from an estimated 2–4 days with cortical tissue slices to only 1–2 h for restoring perfusion after microvascular surgery. Studies in rats found no significant loss of follicles in microvascular ovarian transplants [39], but the technique has only been reported for a single successful human case and, although she has delivered a healthy child and is still cycling with low serum FSH, it is far too early to confirm the degree of advantage in long-term function [5].

Although no firm verdict can yet be drawn, data from the MZ twin series provide striking proof of the effectiveness of fresh cortical transplants and also some reassurance about their reproductive safety. Eight healthy babies have been born to six women. Assisted reproductive technology was not required, natural conception mostly occurring within the first year post-surgery and one instance after the first ovulation. Early conception is not a rule, however, because one woman conceived after 3 years and another had her second child over 4 years after her transplant. It is not surprising that at 40 years old the oldest recipient (#5) has not become pregnant so far, even with the entire cortex of the donor ovary. Ovarian transplants involve a single operation with a relatively low surgical burden and low cost, and the major advantages of no further medicalization of reproduction by IVF, and singleton pregnancies. There have been few miscarriages to date, nor have there been any birth defects or obstetric complications associated with transplantation.

We surmise that careful preparation of the donor tissue as a very thin wafer, avoiding micro-hematoma formation between the highly vascular graft bed, and closely apposing the graft to the medulla, all contributed to the success of this series by prompting rapid revascularization. The orthotopic location may also be important, not only for natural conception but also for avoiding pressure from neighboring tissues, which in some heterotopic sites can distort growing follicles and affect the physiology.

No amount of surgical skill can compensate for poor cryopreservation. The evidence of viability markers indicated that <50% of human oocytes survived the slow-freezing protocol using in 1,2-propanediol, which has been the standard method for ovarian tissue since the pioneering studies in sheep [1, 40–42]. Moreover, ultrastructural studies, which reveal much more detail of cellular injury than histology, have shown major damage from slow-freezing in the stromal tissue which is needed to support follicle growth and provide precursor cells for the theca. Our studies with bovine ovaries have revealed that vitrification can produce results superior to standard cryopreservation [14], a conclusion that was confirmed in the present study although it is too early to report the results of human ovarian tissue transplanted after vitrification. Since most centers including our own have mainly used the slow-freezing cryopreservation protocol, it is reassuring that two viable pregnancies were obtained in our study as well as five others for cancer patients in other centres [6, 11, 12, 43–44]. The percentage of viable oocytes in vitrified tissue was remarkably similar to that of fresh tissue controls, suggesting that vitrification might provide even better results after transplantation than slow freeze cryopreservation.

Finally, what is the future for women whose ovaries were frozen before undergoing treatment of leukemia or breast cancers that might have already metastasized to the ovary [22, 45–54]. Hodgkin's disease is the safest cancer for transplanting ovarian tissue back to the patient [16–19, 55]. The tumors least likely to present with ovarian metastasis are Hodgkins and osteogenic sarcoma. But what can be done with frozen ovarian tissue of the leukemia survivor if there happen to have been leukemic cells in that tissue? Non-Hodgkins lymphomas, colon, melanoma, pancreas, gastric, and breast cancer, often called Krukenberg tumor, can all metastasize to the ovary

[56–60]. Culturing ovarian tissue to obtain mature follicles for IVF in these patients is currently the subject of intense research efforts. The mysterious clockwork of a precise number of follicles leaving the resting pool daily and maturing over the next 3 months has defied efforts at *in vitro* maturation of eggs, which is what is necessary to safely use this tissue for helping leukemia patients conceive. But progress is now being made with three-dimensional culturing because one mechanism controlling follicle maturation in the ovarian cortex may be physical pressure and tissue rigidity. Using this concept, remarkable progress has been made in culturing ovarian tissue and maturing follicles *in vitro* [18]. It could even explain why orthotopic transplantation is so robust and heterotopic results have been so disappointing.

Recent Progress on Culturing Follicles In Vitro

Cryopreserved ovarian tissue can be used for autotransplantation [1, 3–5, 37, 61–62] or *in vitro* maturation of follicles to produce mature oocytes [45]. The latter approach eliminates the possibility of reintroduction of cancer cells and provides a way to harvest a greater number of mature oocytes. However, *in vitro* maturation of ovarian follicles has been fraught with many technical challenges [63–66].

The ovarian follicle is a unique structure that contains the egg surrounded by and intimately connected to support cells. *In vivo* and *in vitro* studies have established the importance of cell–cell communication in the growth and differentiation of the follicle [67]. In traditional 2-D culture systems, somatic cells detach from the oocyte and spread onto the culture surface, thereby disrupting somatic cell–oocyte communication. The inefficiency of oocyte maturation in the 2-D system has been the primary stumbling block to *in vitro* maturation protocols. In contrast, 3-D culture systems maintain the overall architecture of the follicle and therefore support the vital communication pathways between the egg and the somatic cells, thereby more effectively allowing normal follicle development [19, 38, 55, 63, 68–70].

In our 3-D culture system, ovarian follicles are encapsulated within hydrogel beads formed from alginate [68, 70]. Alginate is a linear polysaccharide derived from algae and is composed of repeating units of β -D-mannuronic acid and α -L-guluronic acid [71]. Gelation of alginate by ionic crosslinking of the guluronic residues with calcium is mild, which maintains cell viability. Additionally, alginate has minimal nonspecific protein absorption and cell adhesion and thus serves primarily as a mechanical support to the follicle [72]. Immature follicles can be placed in alginate droplets, which, after gelation, replace the ovarian stroma/matrix and support the 3-D culture of ovarian follicles *in vitro*. Alginate was chosen for encapsulation since immature mouse follicles can be encapsulated easily in alginate hydrogel beads [68, 70]. Follicles can be removed from alginate by degrading the gel with an alginate-specific enzyme, which has no known interactions with mammalian cells. In addition to mechanical support, alginate is highly porous, thereby allowing soluble factors and hormones to diffuse through the gel between the media and the follicle.

Following encapsulation, follicle growth and oocyte maturation during an 8- to 12-day culture period phenocopied follicle development *in vivo*, in which follicles form a central fluid-filled antral cavity and the oocyte is surrounded by cumulus cells [68]. Follicles retrieved from the hydrogel were treated with hCG, and approximately 70% of fully-grown oocytes matured to metaphase II after 16 h. These eggs were fertilized *in vitro* (~68%, $n = 99$) at rates similar to that achieved with *in vivo* ovulated mature eggs (~82%, $n = 65$), indicating that the 3-D hydrogel supports normal oocyte development in a manner far superior to any other method developed to date [19]. Transplantation of embryos derived from follicles cultured in the alginate system into CD1 foster mothers resulted in live births of healthy, fertile offspring from 20% of the transferred embryos, a significant improvement relative to previously reported live birth rates, which are less than 5%.

In vitro and *in vivo* tissue engineering approaches for previously intractable biological problems have gained significant momentum in the past two decades. Application of tissue-engineering principles to reproductive health and fertility preservation has been promising that the biological obstacles to *in vitro* follicle development can be overcome. The success of studies in mice using the hydrogel system present a new opportunity to move this technology from the bench to the bedside and to provide fertility options to patients who have only immature follicles available as starting material.

Monkey ovary cortical strips have been transplanted in a variety of sites *in vivo* with re-initiation of antral follicle growth, oocyte maturation, and, following ICSI and embryo transfer, one live birth [73]. Ongoing studies are assessing factors that impact graft survival and the retention of follicular reserves that will sustain follicle growth and production of healthy, mature oocytes. In 2004, the first human baby was born after orthotopic transplantation of frozen-thawed ovarian tissue in a woman with Hodgkin's lymphoma [6]. Since then there have been several case reports demonstrating that autotransplantation of frozen-thawed ovarian cortical strips can yield human oocytes capable of fertilization and early development [74], pregnancy, and offspring [12, 44]. Thus, the cryopreservation and storage of human ovarian cortex from patients at risk for gametotoxicity during clinical treatments is becoming prevalent and guidelines are being established [75]. Nevertheless, slow-freezing techniques, as well as some transplant techniques, can result in a significant loss of follicles [7, 40, 41] and carry a significant risk of reintroducing cancer cells into the "cured" patient [54, 76]. Newer freezing and surgical techniques discussed in the first part of this chapter have solved the problem of oocyte loss. Nevertheless, autotransplantation of ovarian tissue, especially in young girls, does raise concerns about long-term patient safety [77].

In vitro follicle maturation provides an alternative to autotransplantation by eliminating the risk of reintroducing cancer cells. However, the difficulty of maturing isolated oocytes without their supporting follicle and the failure of small follicles to develop in a 2-D environment have hindered development of *in vitro* follicle maturation strategies. The limitations of 2-D culture systems may be even greater in primates, which have larger follicles with a longer growth phase [78]. Primate [79] and human [80] primordial follicles maintained *in situ* in organ culture (1-mm

slices) will begin to grow and can reach the secondary stage, but a large percentage of follicles are lost. While ovarian slices retain the general architecture of the follicle, the poor diffusion properties and rigid structure of the tissue likely limit follicle growth and development.

The 3-D alginate hydrogel culture system may offer new opportunities for investigating follicle growth and maturation in primates, and, ultimately, for restoring fertility in female patients following ovarian tissue cryopreservation. In contrast to mice [19], there are no reports to date of human follicles achieving the large to preovulatory stages *in vitro* [81]. Current research efforts are aimed at evaluating the growth potential of rhesus monkey preantral and antral follicles encapsulated in the alginate hydrogel matrix. Preliminary experiments have demonstrated that early stage and preantral follicles can be grown *in vitro* to the small and medium antral stage in 24 and 31 days, respectively. This interval is similar to that reported for human follicle culture [81], although success rates appear to be higher. Whether this is due to the use of alginate encapsulation or starting with preantral rather than primordial follicles remains to be determined. Preantral follicles growing to the small antral stage became steroidogenically active, with androgen and estrogen levels rising from low concentrations during the first week of culture to appreciable levels by the end of the second week.

It appears that longer intervals of culture will be required in primates relative to mice to obtain mature preovulatory follicles, and that follicle survival could be dependent upon the phase of the menstrual cycle when ovaries are collected. Nonetheless, initial results provide the first evidence for long-term culture of preantral primate follicles to the antral stage. Future studies will continue to optimize the alginate hydrogel culture system in terms of gel matrix composition and media components, with the goal of producing mature oocytes that are competent for fertilization, culminating in transplantation of embryos and the birth of live, healthy, fertile offspring. Coupled with advances in ovarian tissue cryopreservation, *in vitro* maturation may provide another option for young cancer patients and women who want to preserve fertility without the potential risks associated with autotransplantation.

Conclusions and Final Thoughts

A carefully guarded clinical decision is necessary before transplanting ovarian tissue back to cancer patients. Nonetheless, for patients in whom there is no significant risk of ovarian metastasis, ovary tissue transplant may be quite favorable. These results bode well for applications in oncology, as transplantation of ovarian tissue banked at low temperatures is looking more and more promising as an option for preserving fertility. However, in cases where such transplantation would risk the transmission of cancer cells, there may nonetheless be a good option in the future via ovarian follicle culture and IVF.

Acknowledgments This research was supported by the oncofertility consortium NIH 8UL1DE019587, 5RL1HD058296.

References

1. Gosden RG, Baird DT, et al. Restoration of fertility to oophorectomized sheep by ovarian autografts stored at -196 degrees C. *Hum Reprod.* 1994; 9(4):597–603.
2. Silber SJ, Lenahan KM, et al. Ovarian transplantation between monozygotic twins discordant for premature ovarian failure. *N Engl J Med.* 2005; 353(1):58–63.
3. Silber SJ, DeRosa M, et al. A series of monozygotic twins discordant for ovarian failure: ovary transplantation (cortical versus microvascular) and cryopreservation. *Hum Reprod.* 2008; 23(7):1531–7.
4. Silber SJ, Gosden RG Ovarian transplantation in a series of monozygotic twins discordant for ovarian failure. *N Engl J Med.* 2007; 356(13):1382–4.
5. Silber SJ, Grudzinskas G, et al. Successful pregnancy after microsurgical transplantation of an intact ovary. *N Engl J Med.* 2008; 359(24):2617–8.
6. Donnez J, Dolmans MM, et al. Livebirth after orthotopic transplantation of cryopreserved ovarian tissue. *Lancet.* 2004; 364(9443):1405–10.
7. Baird DT, Webb R, et al. Long-term ovarian function in sheep after ovariectomy and transplantation of autografts stored at -196 C. *Endocrinology.* 1999; 140(1):462–71.
8. Candy CJ, Wood MJ, et al. Restoration of a normal reproductive lifespan after grafting of cryopreserved mouse ovaries. *Hum Reprod.* 2000; 15(6):1300–4.
9. Sanchez M, Alama P, et al. Fresh human orthotopic ovarian cortex transplantation: long-term results. *Hum Reprod.* 2007; 22(3):786–91.
10. Anderson RA, Cameron DA Assessment of the effect of chemotherapy on ovarian function in women with breast cancer. *J Clin Oncol.* 2007; 25(12):1630–1, author reply 1632.
11. Demeestere I, Simon P, et al. Fertility preservation: successful transplantation of cryopreserved ovarian tissue in a young patient previously treated for Hodgkin’s disease. *Oncologist.* 2007; 12(12):1437–42.
12. Meirou D, Levron J, et al. Pregnancy after transplantation of cryopreserved ovarian tissue in a patient with ovarian failure after chemotherapy. *N Engl J Med.* 2005; 353(3):318–21.
13. Donnez J, Martinez-Madrid B, et al. Ovarian tissue cryopreservation and transplantation: a review. *Hum Reprod Update.* 2006; 12(5):519–35.
14. Kagawa N, Silber S, et al. Successful vitrification of bovine and human ovarian tissue. *Reprod Biomed Online.* 2009; 18(4):568–77.
15. Faddy MJ, Gosden RG, et al. Accelerated disappearance of ovarian follicles in mid-life: implications for forecasting menopause. *Hum Reprod.* 1992; 7(10):1342–6.
16. Telfer EE, McLaughlin M, et al. A two-step serum-free culture system supports development of human oocytes from primordial follicles in the presence of activin. *Hum Reprod.* 2008; 23(5):1151–8.
17. West ER, Xu M, et al. Physical properties of alginate hydrogels and their effects on in vitro follicle development. *Biomaterials.* 2007; 28(30):4439–48.
18. West-Farrell ER, Xu M, et al. The mouse follicle microenvironment regulates antrum formation and steroid production: alterations in gene expression profiles. *Biol Reprod.* 2009; 80(3):432–9.
19. Xu M, Kreeger PK, et al. Tissue-engineered follicles produce live, fertile offspring. *Tissue Eng.* 2006; 12(10):2739–46.
20. Arav A, Revel A, et al. Oocyte recovery, embryo development and ovarian function after cryopreservation and transplantation of whole sheep ovary. *Hum Reprod.* 2005; 20(12):3554–9.
21. Bedaiwy MA, Falcone T Harvesting and autotransplantation of vascularized ovarian grafts: approaches and techniques. *Reprod Biomed Online.* 2007; 14(3):360–71.
22. Jeruss JS, Woodruff TK Preservation of fertility in patients with cancer. *N Engl J Med.* 2009; 360(9):902–11.
23. Bleyer WA The impact of childhood cancer on the United States and the world. *CA Cancer J Clin.* 1990; 40(6):355–67.

24. Ries LAG Cancer incidence and survival among children and adolescents: United States SEER program 1975–1995. Bethesda: National Cancer Institute; 1999.
25. Anderson RA, Themmen AP, et al. The effects of chemotherapy and long-term gonadotrophin suppression on the ovarian reserve in premenopausal women with breast cancer. *Hum Reprod*. 2006; 21(10):2583–92.
26. Meirou D, Nugent D The effects of radiotherapy and chemotherapy on female reproduction. *Hum Reprod Update*. 2001; 7(6):535–43.
27. Meirou D, Schenker JG The link between female infertility and cancer: epidemiology and possible aetiologies. *Hum Reprod Update*. 1996; 2(1):63–75.
28. Schover LR, Brey K, et al. Knowledge and experience regarding cancer, infertility, and sperm banking in younger male survivors. *J Clin Oncol*. 2002; 20(7):1880–9.
29. Schover LR, Rybicki LA, et al. Having children after cancer. A pilot survey of survivors' attitudes and experiences. *Cancer*. 1999; 86(4):697–709.
30. Homburg R, van der Veen F, Silber SJ Oocyte vitrification – Women's emancipation set in stone. *Fertil Steril*. 2009; 91(4):1319–20.
31. Lampic C, Svanberg AS, et al. Fertility awareness, intentions concerning childbearing, and attitudes towards parenthood among female and male academics. *Hum Reprod*. 2006; 21(2):558–64.
32. Leridon H Can assisted reproduction technology compensate for the natural decline in fertility with age? A model assessment. *Hum Reprod*. 2004; 19(7):1548–53.
33. Maheshwari A, Porter M, et al. Women's awareness and perceptions of delay in childbearing. *Fertil Steril*. 2008; 90(4):1036–42.
34. Devroey P Female age predicts embryonic implantation after ICSI: a case-controlled study. *Hum Reprod*. 1996; 11(6):1324–7.
35. Fretts RC. Effect of advanced age on fertility and pregnancy in women. In: Up to date online. <http://www.uptodate.com>; 2007.
36. SART. Assisted reproductive technology success rates. National summary and fertility clinic reports. Atlanta: Centers for Disease Control and Prevention; 2005.
37. Silber SJ, Nagy Z, et al. The effect of female age and ovarian reserve on pregnancy rate in male infertility: treatment of azoospermia with sperm retrieval and intracytoplasmic sperm injection. *Hum Reprod*. 1997; 12(12):2693–700.
38. Spears N, Boland NI, et al. Mouse oocytes derived from in vitro grown primary ovarian follicles are fertile. *Hum Reprod*. 1994; 9(3):527–32.
39. Yin H, Wang X, Kim SS, Chen H, Tan SL, Gosden RG. Transplantation of intact rat gonads using vascular anastomosis: effects of cryopreservation, ischaemia and genotype. *Hum Reprod*. 2003; 18:1165–1172.
40. Aubard Y, Piver P, et al. Orthotopic and heterotopic autografts of frozen-thawed ovarian cortex in sheep. *Hum Reprod*. 1999; 14(8):2149–54.
41. Newton H, Aubard Y, et al. Low temperature storage and grafting of human ovarian tissue. *Hum Reprod*. 1996; 11(7):1487–91.
42. Salle B, Lornage J, Demirci B, Vaudoyer F, Poirrel MT, Franck M, Rudigoz RC, Guerin JF. Restoration of ovarian steroid secretion and histologic assessment after freezing, thawing and autograft of a hemi-ovary in sheep. *Fertil Steril*. 1999; 72:366–370.
43. Andersen CY, Rosendahl M, Byskov AG, Loft A, Ottosen C, Dueholm M, Schmidt KLT, Andersen AY, Ernst E. Two successful pregnancies following autotransplantation of frozen/thawed ovarian tissue. *Hum Reprod*. 2008; 23:2266–2272.
44. Demeestere I, Simon P, et al. Ovarian function and spontaneous pregnancy after combined heterotopic and orthotopic cryopreserved ovarian tissue transplantation in a patient previously treated with bone marrow transplantation: case report. *Hum Reprod*. 2006; 21(8):2010–14.
45. Falcone T, Attaran M, Bedaiwy MA, Goldberg JM. Ovarian function preservation in the cancer patient. *Fertil Steril*. 2004; 81:243–257.
46. Gadducci A, Cosio S, Genazzani AR. Ovarian function and childbearing issues in breast cancer survivors. *Gynecol Endocrinol*. 2007; 23:625–631.

47. Jemal A, Siegel R, Ward E, Hao Y, Xu J, Murray T, Thun MJ. Cancer statistics, 2008. *CA Cancer J Clin.* 2008; 58:71–96.
48. Lobo RA. Potential options for preservation of fertility in women. *N Engl J Med.* 2005; 353:64–73.
49. Colgan TJ, Murphy J, Cole DE, Narod S, Rosen B. Occult carcinoma in prophylactic oophorectomy specimens: prevalence and association with BRCA germline mutation status. *Am J Surg Pathol.* 2001; 25:1283–1289.
50. Elizur SE. Detection of microscopic metastasis of solid tumors and hematological malignancies in cryopreserved ovaries. *Fertil Steril.* 2004; 82.
51. Meirow D, Hardan I, Dor J, Fridman E, Elizur S, Ra'anani H, Slyusarevsky E, Amariglio N, Schiff E, Rechavi G, Nagler A, Ben Yehuda D. Searching for evidence of disease and malignant cell contamination in ovarian tissue stored from hematologic cancer patients. *Hum Reprod.* 2008; 23:1007–1013.
52. Nakayama K. Gonadal failure after treatment of hematologic malignancies: from recognition to management for health-care providers. *Nat Clin Pract Oncol.* 2008; 5:78–89.
53. Sklar CA, Mertens AC, Mitby P, Whitton J, Stovall M, Kasper C, Mulder J, Green D, Nicholson HS, Yasui Y, Robison LL. Premature menopause in survivors of childhood cancer: a report from the childhood cancer survivor study. *J Natl Cancer Inst.* 2006; 98:890–896.
54. Schroder CP, Timmer-Bosscha H, et al. An in vitro model for purging of tumour cells from ovarian tissue. *Hum Reprod.* 2004; 19(5):1069–75.
55. Xu M, West E, et al. Identification of a stage-specific permissive in vitro culture environment for follicle growth and oocyte development. *Biol Reprod.* 2006; 75(6):916–23.
56. Monterosso V, Jaffe ES, Merino MJ, Medeiros LJ. Malignant lymphomas involving the ovary: a clinicopathologic analysis of 39 cases. *Am J Surg Pathol.* 1993; 17:154–170.
57. Perlman S, Ben-Arie A, Feldberg E, Hagay Z. Non-Hodgkins lymphoma presenting as advanced ovarian cancer: a case report and review of the literature. *Int J Gynecol Cancer.* 2005; 15:554–557.
58. Fox H, Langley FA, Govan AD, Hill AS, Bennett MH. Malignant lymphoma presenting as an ovarian tumor: a clinicopathologic analysis of 34 cases. *Br Obstet Gynecol.* 1998; 105.
59. Kim JW, Cho M-K, Cheo HK, et al. Ovarian and multiple lymph nodes recurrence of acute lymphoblastic leukemia: a case report and review of the literature. *Ped Surg Intl.* 2008; 24:1269–1273.
60. Elharoudi H, Ismali N, Ernihani H, Jalil A. Primary lymphoma of the ovary. *J Cancer. Res Ther.* 2008; 4:195–196.
61. Gosden RG, Newton H, et al. The cryopreservation of human ovarian tissue. In: Kempers RD, Cohen J, Haney AF, Younger JB, Eds. *Fertility and reproductive medicine. Proceedings of the XVI world congress on fertility and sterility.* Amsterdam: Elsevier; 1998:615–20.
62. Eppig JJ, O'Brien MJ. Development in vitro of mouse oocytes from primordial follicles. *Biol Reprod.* 1996; 54(1):197–207.
63. Cortvrindt R, Smitz J, et al. In-vitro maturation, fertilization and embryo development of immature oocytes from early preantral follicles from prepuberal mice in a simplified culture system. *Hum Reprod.* 1996; 11(12):2656–66.
64. Nogueira D, Cortvrindt R, et al. Effects of long-term in vitro exposure to phosphodiesterase type-3 inhibitors on follicle and oocyte development. *Reproduction.* 2005; 130(2): 177–86.
65. Papanikolaou EG, Platteau P, et al. Immature oocyte in-vitro maturation: clinical aspects. *Reprod Biomed Online.* 2005; 10(5):587–92.
66. Smitz J, Picton HM, et al. Principal findings from a multicenter trial investigating the safety of follicular-fluid meiosis-activating sterol for in vitro maturation of human cumulus-enclosed oocytes. *Fertil Steril.* 2007; 87(4):949–64.
67. Matzuk MM, Burns KH, et al. Intercellular communication in the mammalian ovary: oocytes carry the conversation. *Science.* 2002; 296(5576):2178–80.

68. Kreeger PK, Fernandes NN, et al. Regulation of mouse follicle development by follicle-stimulating hormone in a three-dimensional in vitro culture system is dependent on follicle stage and dose. *Biol Reprod.* 2005; 73(5):942–50.
69. O'Brien MJ, Pendola JK, et al. A revised protocol for in vitro development of mouse oocytes from primordial follicles dramatically improves their developmental competence. *Biol Reprod.* 2003; 68(5):1682–6.
70. Pangas SA, Saudye H, et al. Novel approach for the three-dimensional culture of granulosa cell-oocyte complexes. *Tissue Eng.* 2003; 9(5):1013–21.
71. Amsden B, Turner N Diffusion characteristics of calcium alginate gels. *Biotechnol Bioeng.* 1999; 65(5):605–10.
72. Rowley JA, Madlambayan G, et al. Alginate hydrogels as synthetic extracellular matrix materials. *Biomaterials.* 1999; 20(1):45–53.
73. Lee DM, Yeoman RR, et al. Live birth after ovarian tissue transplant. *Nature.* 2004; 428(6979):137–8.
74. Oktay K, Buyuk E, et al. Embryo development after heterotopic transplantation of cryopreserved ovarian tissue. *Lancet.* 2004; 363(9412):837–40.
75. Gunasena KT, Villines PM, et al. Live births after autologous transplant of cryopreserved mouse ovaries. *Hum Reprod.* 1997; 12(1):101–6.
76. Shaw JM, Bowles J, et al. Fresh and cryopreserved ovarian tissue samples from donors with lymphoma transmit the cancer to graft recipients. *Hum Reprod.* 1996; 11(8):1668–73.
77. Jahnukainen K, Ehmcke J, et al. Clinical potential and putative risks of fertility preservation in children utilizing gonadal tissue or germline stem cells. *Pediatr Res.* 2006; 59(4 Pt 2): 40R–47R.
78. Abir R, Fisch B, et al. Morphological study of fully and partially isolated early human follicles. *Fertil Steril.* 2001; 75(1):141–6.
79. Wandji SA, Srsen V, et al. Initiation of growth of baboon primordial follicles in vitro. *Hum Reprod.* 1997; 12(9):1993–2001.
80. Abir R, Nitke S, et al. In vitro maturation of human primordial ovarian follicles: clinical significance, progress in mammals, and methods for growth evaluation. *Histol Histopathol.* 2006; 21(8):887–98.
81. Picton HM, Harris SE, et al. Prospects for follicle culture. In: Tulandi T, Gosden RG, Eds. *Preservation of fertility.* New York: Taylor & Francis; 2004:191–205.